

# A PILOT STUDY TO ASSESS THE EFFICACY AND SAFETY OF A NOVEL INTELLIGENT ELECTRO-MUSCULAR STIMULATION SYSTEM, ACCUFIT™, IN AESTHETIC PRACTICE

W. LOVERME, MD AND R. G. CALDERHEAD M. SC., PH.D

## Background & Aims

Stimulation of muscles for improved strength and tonicity has historically been achieved with electrical energy (electro-muscular stimulation, EMS) directly applied to the skin so that discomfort can often limit the amount of current applied thereby limiting efficacy. Functional magnetic stimulation (FMS) uses an alternating magnetic field to stimulate muscle action, which bypasses through the skin with no adverse effects. Lutronic has therefore developed Accufit™, a third-generation system that re-imagines direct electrical stimulation for aesthetic practice by using a novel electrode design that minimizes skin discomfort while maximizing stimulation of muscle groups with a set of unique waveforms. This combines the best facets of FMS and EMS in the one system. These unique waveforms enable various muscle contractions both concentric and eccentric to emulate four different exercise patterns ('Twist', 'Hold' 'Grip', and 'Tap'), by themselves or in sequence, controlled by an intelligent real-time impedance feedback system. The present IRB-approved pilot study was designed to test the safety and efficacy of Accufit in the abdominal muscles.

## Subjects & Methods

Thirty-seven subjects (27 females and 10 males) enrolled for the study to assess improvement in abdominal muscle strength, tonicity, and abdominal appearance following a regimen of treatments with Lutronic's Bioelectric Muscle Activation (BMA) device, the Accufit. Three subjects failed to complete the treatment protocol and five others were lost to follow-up. Twenty-nine subjects formed the final study population (25 Caucasian skin type, 4 Asian skin type III, ages ranging from 25 – 61 yr, median age 48, and mean age 45.82±10.8). The period of the study from enrollment to completion of all follow-up was from the beginning of August till mid-December 2020. All subjects received four 30-min Accufit treatment sessions in Auto mode—twice weekly for 2 weeks and at least 48 hr apart. While pain scores were taken during each session, clinical photography and video records were made at baseline, during each session, and at the 30-day assessment after the final treatment. Weight and abdominal circumference were measured at baseline and at the 30-day assessment. At this time, subjects completed a questionnaire assessing subjective aspects of their goals and whether they were met, overall comfort of the treatment, and satisfaction with overall abdominal improvement including willingness to recommend Accufit treatment to friends and family. Independent randomized expert grading of the clinical photography was carried out. Four subjects volunteered for ultrasound assessment of changes in abdominal architecture.

## Results

All 29 subjects completed the final questionnaire. Of these subjects, 14 were very satisfied with the improvement in the tone and appearance of their abdomens and flanks. As for the results of the others: 13 were satisfied, 1 was neutral and 1 was dissatisfied. Overall, 93% were satisfied or better. In addition, twenty-eight of the 29 subjects would be happy to recommend the treatment to friends or family. A tingling sensation and pressure were commonly reported during treatment. While pain and retrospective comfort scores were generally low and more or less the same, the retrospectively assessed comfort score was often lower than the intra-treatment pain score. Gains in muscle tone and strength and improved abdominal contour were reported. The majority of the subjects (18) showed a modest weight loss (average 2.23 lbs) whereas 3 subjects remained the same weight, and the remaining 8 showed minor gains (average 1.83 lbs). Seventeen of the subjects demonstrated a minor decrease in abdominal circumference (average 0.91"), 10 remained the same, and the remaining 2 gained 1". However, as subject lifestyle was not mandated as part of the trial protocol, it was impossible to state that these weight and circumferential changes were directly related to the effects of the Accufit regimen. The independent randomized expert grading of the clinical photography correctly identified the treated versus the baseline photography in the great majority of cases with a concordance rating of 90%. Ultrasound imaging showed in general an increase in abdominal muscle thickness (Average 19% increase at 1 month post treatments) with a decrease in the abdominal fat layer for most patients (Average of 29% reduction at 1 month post treatments).

## Conclusions

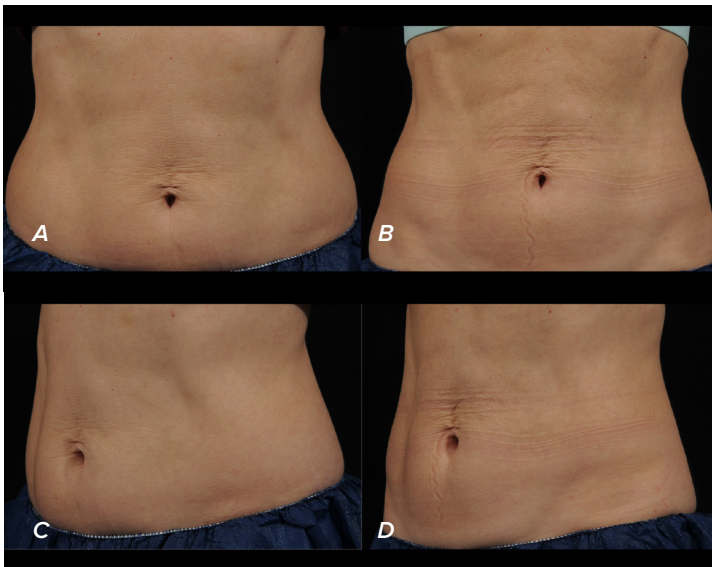
More than 90% of the pilot study subjects were satisfied with the overall improvement in their abdominal and flank appearance following 4 treatment sessions spanning over 2 weeks with Accufit. Subjects also felt that their goals had been met and all but one would be happy to recommend the treatment to their friends. In addition, there were no adverse events and pain scores were low. The data showed that the Bioelectric Muscle Activation Device used in our study produced a consistent, observable reduction in abdominal contour versus baseline—which is consistent with the findings in both the ultrasound measurements and blinded expert grading. Based on the very optimistic results of the present pilot study, further controlled studies with larger populations are warranted to confirm the safety and efficacy of Accufit as a novel third-generation direct bio-electrical muscle stimulator.

**Key words:** Electro-muscular stimulation; functional magnetic stimulation; core strength; multi-waveform sequence; contouring.

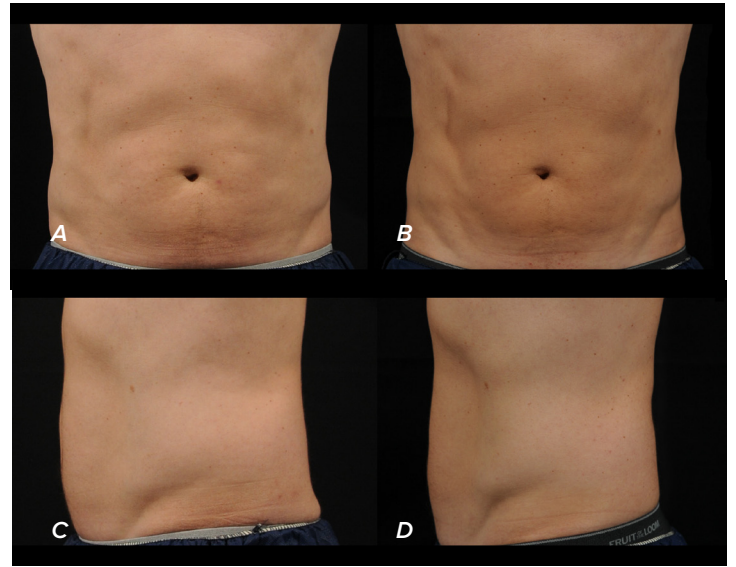
## SUMMARY OF RESULTS

### Ultrasound Image Assessment Chart

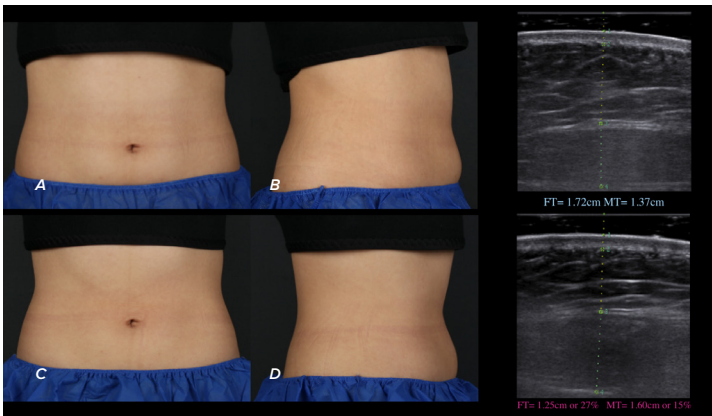
Pt No.	Fat Thickness					Muscle Thickness				
	Pre Treatment	Immediately Post 4 Sessions	% Change	1 Month Post	% Change	Pre Treatment	Immediately Post 4 Sessions	% Change	1 Month Post	% Change
34	0.98	0.7	28%	0.69	41%	1.53	1.96	22%	1.98	23%
35	1.63	1.32	31%	1.43	15%	0.77	1.26	39%	0.93	17%
36	1.72	1.52	20%	1.25	31%	1.37	1.57	13%	1.6	15%
37	1.2	0.9	30%	0.95	28%	1.72	2.14	20%	2.21	22%
<b>Average</b>	<b>1.3825</b>	<b>1.11</b>	<b>27%</b>	<b>1.08</b>	<b>29%</b>	<b>1.3475</b>	<b>1.7325</b>	<b>23%</b>	<b>1.68</b>	<b>19%</b>



Accufit treatment in a 43-year-old female (Patient 27). (a): At baseline. (b): At the 30-day assessment following the final treatment session, with weight loss of 1.2 lbs and circumferential reduction of 0.5". She was very satisfied with the result.

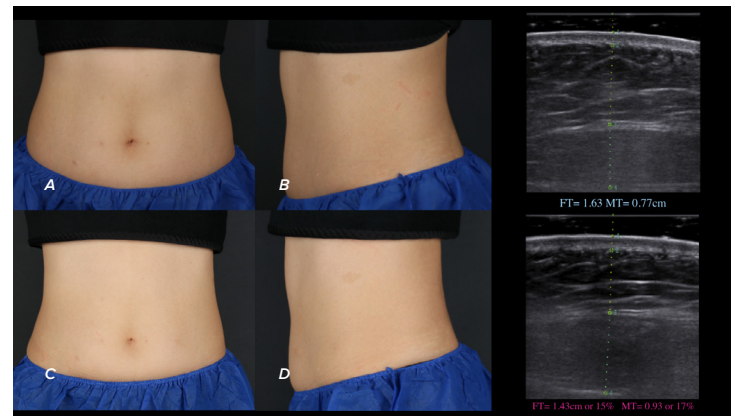


Accufit treatment in a 54-year-old male (Patient 8). (a): At baseline. (b): At the 30-day assessment following the final treatment session. This patient recorded a weight reduction of 1.4 lbs and a circumferential loss at the umbilicus of 0.5". He was very satisfied with the result.



Accufit treatment in a 27-year-old female (Patient 36) (a): At baseline. (b): At the 30-day assessment following the final treatment session. This patient recorded a weight gain of 0.9 lbs and no circumferential loss at the umbilicus He was satisfied with the result.

Ultrasonography findings in a 27-year-old female (Patient 36 seen in Figure 8 above). (a): At Baseline. (b) The findings at 1 month after the final treatment. There is a 27% reduction in the fat compartment (1.72 cm to 1.25 cm), and a 15% increase in the muscle (1.37 cm to 1.60 cm).



Accufit treatment in a 52-year-old female (Patient 35). (a): At baseline. (b): At the 30-day assessment following the final treatment session, with no weight loss and a circumferential reduction of 0.5". This patient was satisfied with the result.

Ultrasonography findings in a 52-year-old female (Patient 35 seen in Figure 7 above). (a): At Baseline. (b) The findings at 1 month after the final treatment. There is a 22% reduction in the fat compartment (1.66 cm to 1.33 cm), and a 25% increase in the muscle (0.76 cm to 1.09 cm).

FT= Fat Thickness MT= Muscle Thickness